

Quilting Sutures versus Suprascarp's Dissection in Reduction of Seroma Formation Following Abdominoplasty

Mohamed T. Younis M.D.; Gamal Ibrahim El-Habaa M.D.;

Israa M. Elbazz M. B, B. Ch.; Mohamed H. Abdel Halim M.D.

Plastic Surgery Unit, General Surgery Department, Faculty of Medicine, Benha University, Egypt

ABSTRACT

Background Abdominoplasty surgery is used to enhance body quality and shaping body contours. Massive weight reduction causes an overabundance of superfluous skin that causes additional psychological and functional issues. The most frequent post-abdominoplasty consequence is seroma, which often develops in the second postoperative week in areas where the skin of the trunk is compromised or dead space is produced. Several prophylactic measures have been proposed to reduce the prevalence of postoperative seroma, including drains, the use of compression garments, tissue adhesives, quilting Sutures and Suprascarp's fascia preservation.

Objectives: The purpose of this study is to assess the efficacy of suprascarp's dissection and quilting sutures in reducing seroma production after abdominoplasty in regarding the quantity of seroma, duration of drain, length of hospital stay, patient satisfaction, and ultimate cosmetic result.

Patients and methods: This study includes 30 female patients at the Plastic Surgery Unit. All of the patients met the following criteria: all patients had a BMI of less than 30, all patients have excess abdominal skin and fat tissue, and all patients exhibit musculoaponeurotic laxity. Between June 2022 and June 2023, our prospective study was carried out at the Benha University Hospital's Plastic Surgery unit. 15 patients had abdominoplasty using the quilting suture technique, while 15 others had them using Scarpa's fascia preservation.

Results: 8 patients had pendulous abdomen post weight gain, 7 patients presented with redundant skin following dietary weight loss, 8 patients presented with abdominal deformities post bariatric surgery and 7 patients presented with skin laxity following multiple pregnancies. Regarding the complications, 14 patients had no complications, 8 patients with seroma, 6 patients with hematoma and 2 patients with wound dehiscence

Conclusion: Suprascarp's fascia preservation and quilting sutures are effective in preserving abdominal wall lymphatics and decreasing postoperative complications especially; decreasing seroma rates, reducing drain duration and hospital stays.

Key words: Seroma post abdominoplasty, Suprascarp's fascia preservation, quilting sutures

Ethical committee: Approval: was obtained for this study from the Ethical Committee of Faculty of Medicine, Benha University. An informed written consent was obtained from all patients regarding surgical procedures and publication of their photos.

Disclosure: No conflict of interest

Corresponding author: israaelbazz94@gmail.com

INTRODUCTION

Abdominoplasty is a body reshaping surgical procedure that has been proven to enhance the patient's quality of life. With a considerable and long-lasting weight loss and a concomitantly significant increase in overall quality of life [1].

As any surgical operation, it is associated with risks and multiple complications, primarily that of seroma formation. The most frequent post-abdominoplasty consequence is seroma, which often develops in the second postoperative week in areas where the skin of the trunk is compromised or dead space is created. Even though it is a self-contained occurrence, it can occasionally be quite problematic. The pressure created by an excessive seroma buildup might be transferred to the flap, leading to flap necrosis and wound dehiscence. Infection risk increases if it becomes contaminated. After an abdominoplasty, there are

uncommon side effects include prolonged liquid buildup and **pseudo cyst** development. Drains, the use of compression garments, tissue adhesives, quilting Sutures, and **suprascarp's fascia preservation** have all been suggested as prophylactic strategies to lower the incidence of postoperative seroma [2,3].

The Quilting sutures and Scarpa's fascia preservation had almost postoperative outcomes in improvement **post abdominoplasty** complications. Scarpa's fascia preservation was linked to minimal dissection, midline musculoaponeurotic plication, reduced seroma development, total drain output, the amount of time suction drains needed to work, and a shorter hospital stay [4].

Compared to traditional abdominoplasty, **Scarpa's** fascia preservation and **quilting sutures** have effective role on preservation of abdominal wall lymphatics, decrease dead space and prevent shearing forces lead to seroma [4,5].

Patients and methods

This case series was created as a prospective study that was carried out at plastic surgery unit, General surgery department of the Benha University Hospital following clearance from the research ethical committee of the Benha Faculty of Medicine. All participants in the study will sign informed consent forms. To ensure quality and consistency in the delivery of the intervention. For this study, 30 Patients who had abdominal abnormalities with excess abdominal skin, fatty tissue, and lax muscle appeared. be recruited to our study with exclusion of Age less than 21 or more than 55 years, Patients with Regular drug intake especially anticoagulants, Patients with uncontrolled comorbidities e.g. DM, hypertension or other uncontrolled comorbidities and Body mass index above 30. The patients were admitted to the general surgery department in Benha **University** Hospital within the period from **June 2022** to **June 2023**.

Patient's ages ranged from 21 to 55, with an average of 38. As preoperative evaluation, renal function test, liver function test, measurement of hemoglobin level, hematocrit, prothrombin time, glucose level and viral markers were required, besides clinical and cardiological evaluation. Besides that, abdominal U/S was done. Patients were given a pre-operative single dose of antibiotic. The patients received General anesthesia during abdominoplasty.

Surgical technique

Surgical options vary from Scarpa's fascia preservation (group A) and Quilting sutures (group B).

Group A: An abdominoplasty with preservation of the Scarpa's fascia was done. The **Scarpa's** fascia level, which could be distinguished by its sparkling white appearance, was the extent of the first incision. After exposing the central portion of the Scarpa's fascia, we continued the incision laterally over it, retaining the lateral portions and adjacent sub-Scarpal fatty areolar layer to protect the lymphatics.

By dividing the fascia along the midline until it reached the level of the rectus muscle fascia, Scarpa was able to create fascia flaps below the umbilicus.

A bilateral wedge-shaped excision from the middle region of the Scarpa was performed after the Scarpa's were separated from the loose tissues beneath them was carried out to avoid supra-pubic bulge (with the base directed upward or downward for better contour, measuring around 4 to 6 cm width between its two limbs). Then, using continuous, non-absorbable sutures placed under tension, the fascial flaps were stitched to each other, the linea alba, or the underlying rectus fascia. Two closed system suction drains were left beneath the flaps, the navel was sutured in two layers, with an interrupted absorbable monofilament 3/0 in the deep dermis, and a running absorbable monofilament 4/0 subcuticular for skin closure.

Group B: An abdominoplasty with quilting sutures was done. Sutures are inserted between the **abdominal skin** flap and the underlying **fascia** to hold the abdominal flap in place while it is progressed. Tension is transmitted distally and the flap is advanced as each suture is applied in turn. The surface fascial system is under tension, not the skin or the subdermal plexus underneath it. The wide region of the flap as well as the weak distal flap are all affected by the stress.

A) Upper Abdomen:

In order to level the patient's position and the surgical area, the patient is flexed at the hips and put in the Trendelenburg position. Hip flexion is usually at a 45° **angle; however**, this varies depending on the patient. Due to the progressive tension sutures' potent progression, considerable bending is not required. Operating is made simpler by avoiding excessive flexion since it is less constrained.

The suture is inserted by the dominant hand into the flap at its highest midline point, and it is then progressed 1-2 cm into **the underlying fascia**.

B- Lower Abdomen:

Once the umbilical inset is finished, progressive tension sutures are placed continuously until the abdominal flap reaches the inferior wound margin. Midline development has been the most significant. Since these sutures are under the greatest strain, 0 Vicryl is frequently used. Lateral sutures are added, albeit with less progress, to secure the flap.

When there is less strain, 2-0 Vicryl is frequently more suitable. The amount of sutures required to hold the flap in place and remove any dead space dictates where the lateral sutures should be placed. A running absorbable monofilament 4/0 subcuticular was used to seal the skin after the navel was sutured in two layers using an interrupted absorbable monofilament 3/0 in the deep dermis.

RESULTS

Among these 30 patients, 15 patients (group A) underwent abdominoplasty with Scarpa's fascia preservation (50%), while the other 15 patients (group B) underwent abdominoplasty with quilting sutures technique (50%). The ages ranged from 21 to 55. (Table 1).

Table (1): General characteristics of the studied groups

	Group A (n = 15)	Group B (n = 15)	P-value
Age (years)	37 ±2	38 ±2	0.612
Weight (kg)	83 ±5	80 ±7	0.225
Height (cm)	158 ±6	156 ±4	0.350
BMI	33 ±3	32 ±3	0.710

In 8 patients had pendulous abdomen post weight gain, 7 patients presented with redundant skin following dietary weight loss, 8 patients presented with abdominal deformities post bariatric surgery and 7 patients presented by skin laxity following multiple pregnancies. (Table 2)

Table (2): Etiology in the studied group

Aetiology	Group A (n = 15)	Group B (n = 15)	P-value
Multiple pregnancies	4 (26.7)	4 (26.7)	1.0
Post-bariatric	4 (26.7)	3 (20)	
Weight gain	4 (26.7)	4 (26.7)	
Weight loss	3 (20)	4 (26.7)	

Group A demonstrated significantly lower drain output compared to group B (113.7 ±6.7 vs. 148 ±10.8, $P < 0.001$). Liposuction was reported in all studied patients in both groups. Additionally, no significant difference was reported in operative time ($P = 0.744$). No postoperative blood transfusion was reported in the studied groups, and the duration was 5 days in both groups (Table 3).

Table (3): Operative and postoperative findings in the studied groups

		Group A (n = 15)	Group B (n = 15)	P-value
Liposuction	n (%)	15 (100)	15 (100)	-

Operative time (h)	Median (range)	3 (2 – 3)	2 (2 – 3)	0.744
Post-op blood transfusion	n (%)	0 (0)	0 (0)	-
Drain duration (days)				
Five days	n (%)	15 (100)	15 (100)	-
Drain output	Mean \pm SD	113.7 \pm 6.7	148 \pm 10.8	<0.001

Regarding waist **circumference**, no significant difference was observed between the studied groups regarding WC pre ($P = 0.751$). In contrast, post-operatively, group A demonstrated significantly lower WC (90 ± 5) than group B (93 ± 4) ($P = 0.03$) (Table 4).

Table (4): Pre and postoperative waist circumference in the studied groups

		Group A (n = 15)	Group B (n = 15)	P-value
WC pre	Mean \pm SD	104 \pm 2	104 \pm 2	0.751
WC post	Mean \pm SD	90 \pm 5	93 \pm 4	0.030

There were no complications in 10 patients of group A, 4 patients of group B. There was no significant difference between both groups as regard postoperative seroma in 3 patients in group A and 5 patients in group B, P value was 0.409. There was no significant difference between both groups as regard: Hematoma 2 patients in group A and 4 patients in group B, P value **0.651**. Also zero patients of group a not developed wound dehiscence while 2 patients of group B, P value **0.483**. There were no cases recorded in both groups regarding wound infection or flap necrosis (Table 5).

Table (5): Complications in the studied groups

		Group A (n = 15)	Group B (n = 15)	P-value
Seroma	n (%)	3 (20.0)	5 (33.3)	0.409
Hematoma	n (%)	2 (13.3)	4 (26.7)	0.651
Wound dehiscence	n (%)	0 (0.0)	2 (13.3)	0.483
Wound infection	n (%)	0 (0.0)	0 (0.0)	-
Flap necrosis	n (%)	0 (0.0)	0 (0.0)	-

Regarding Patient satisfaction, there was no significant difference observed between the studied groups regarding patient satisfaction ($P = 0.408$) (Table 6).

Table (6): Patient satisfaction in the studied groups

	Group A (n = 15)	Group B (n = 15)	P-value
Patient satisfaction			
Highly satisfied	5 (33.3)	3 (20)	0.408
Satisfied	6 (40)	3 (20)	
Not satisfied	2 (13.3)	4 (26.7)	
Highly not satisfied	2 (13.3)	5 (33.3)	

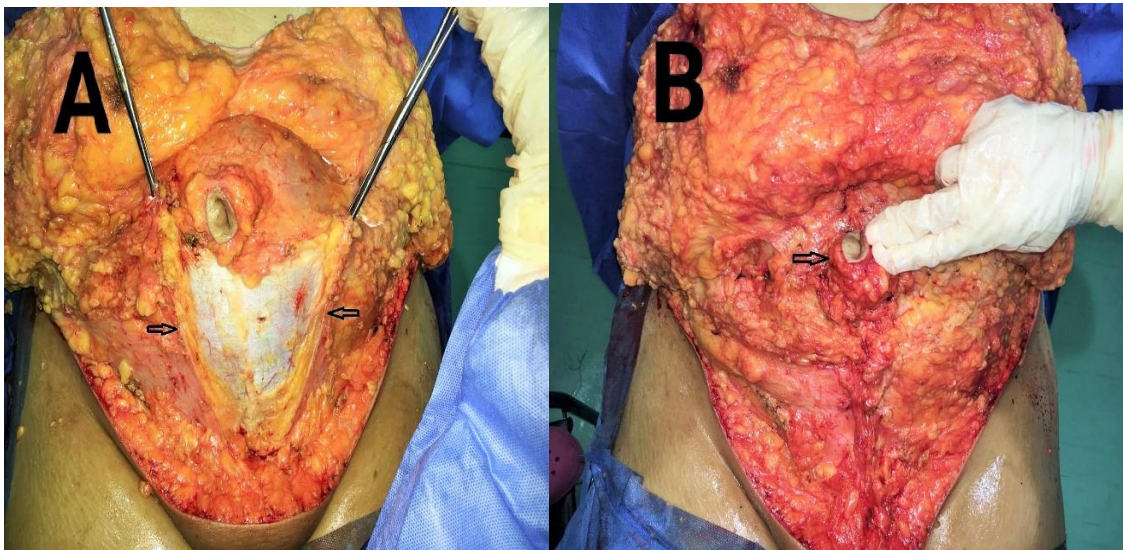


Fig. (1): Intraoperative **Suprascarpa's fascia** preservation ,arrows in photo A refer to **Suprascarpa's space** ,arrow in photo B refer to umbilicus .

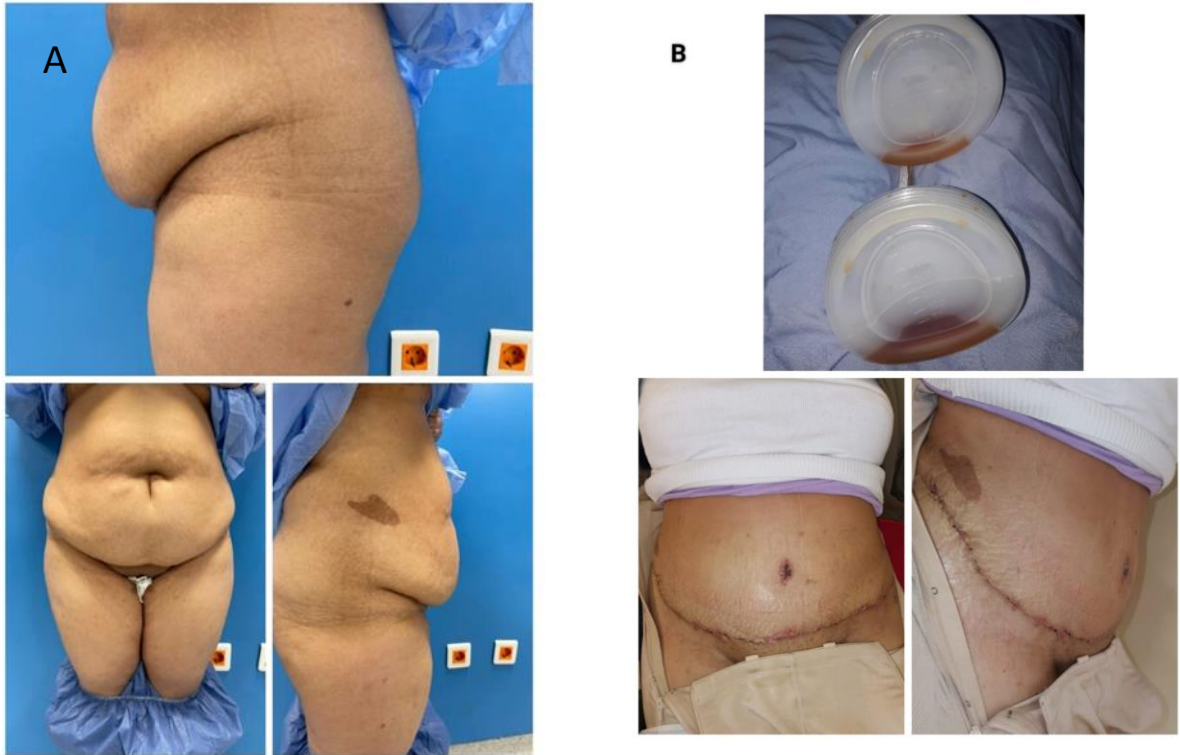


Fig. (2): Female patient 38 y old presented by pendulous abdomen following multiple pregnancy
Note: (A) preoperative photo with pendulous abdomen, (B) 5 days post abdominoplasty with **suprascarp's fascia preservation.**

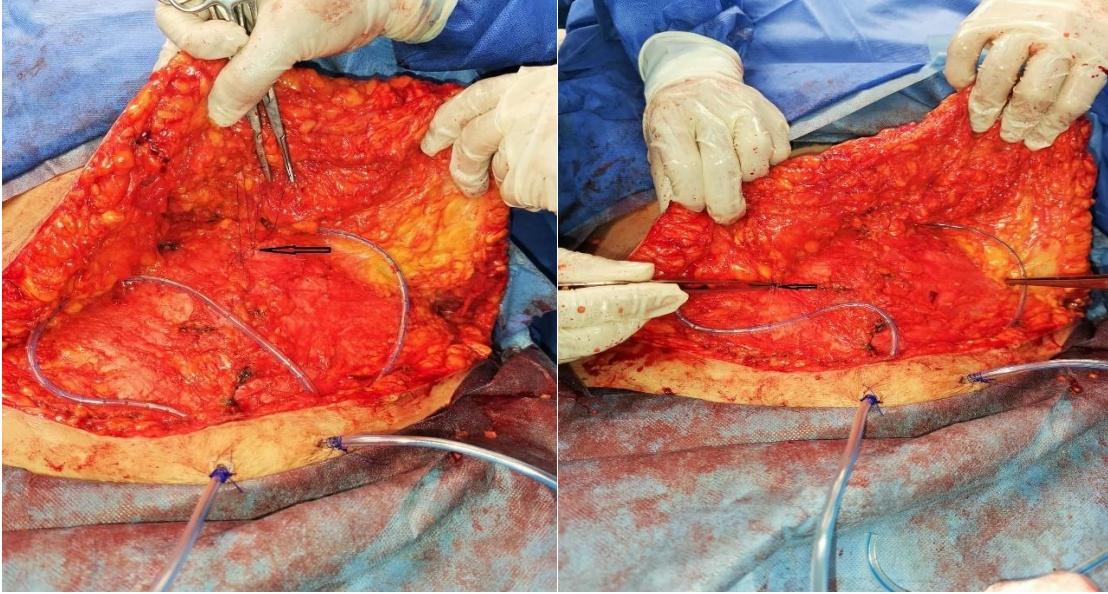


Fig. (3): Intraoperative. quilting sutures; arrows in both photos refer to quilting sutures.

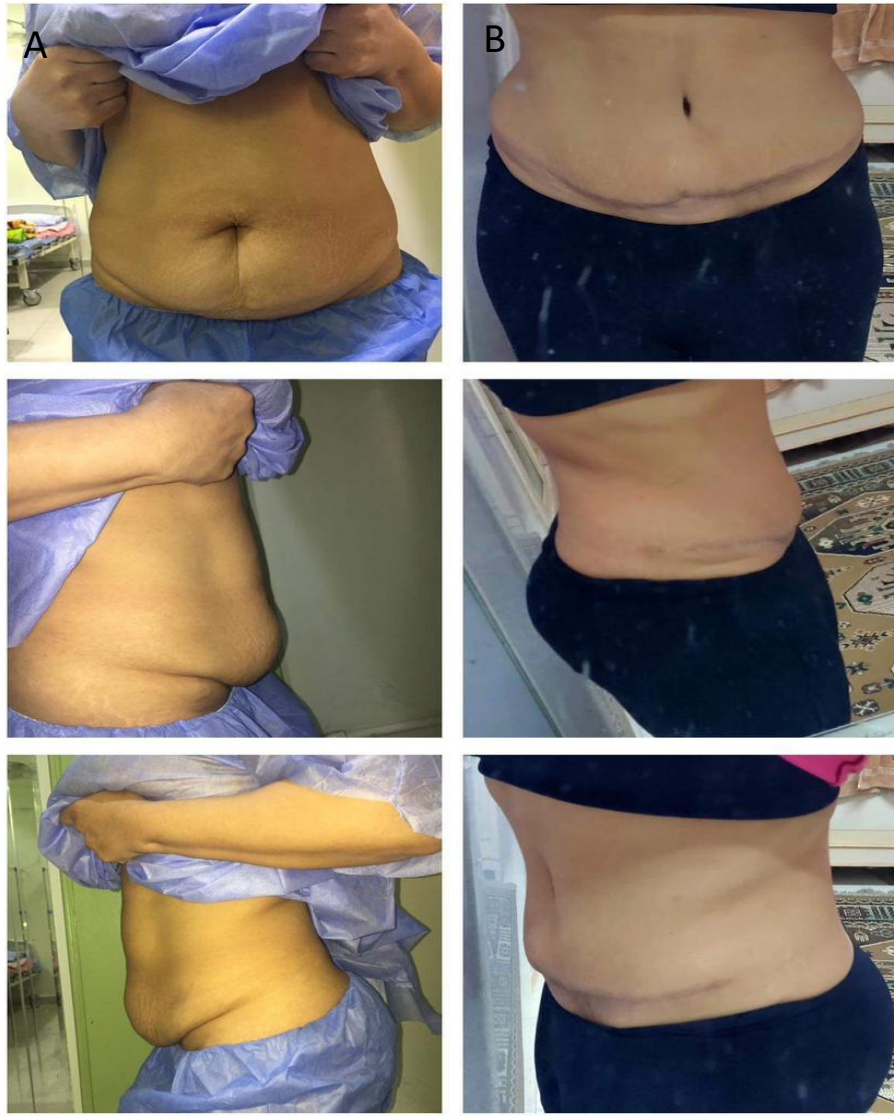


Fig. (4): Female patient 43 y old presented by pendulous abdomen following multiple pregnancy
Note: (A) preoperative photo, figure (B) abdominoplasty with quilting sutures was done

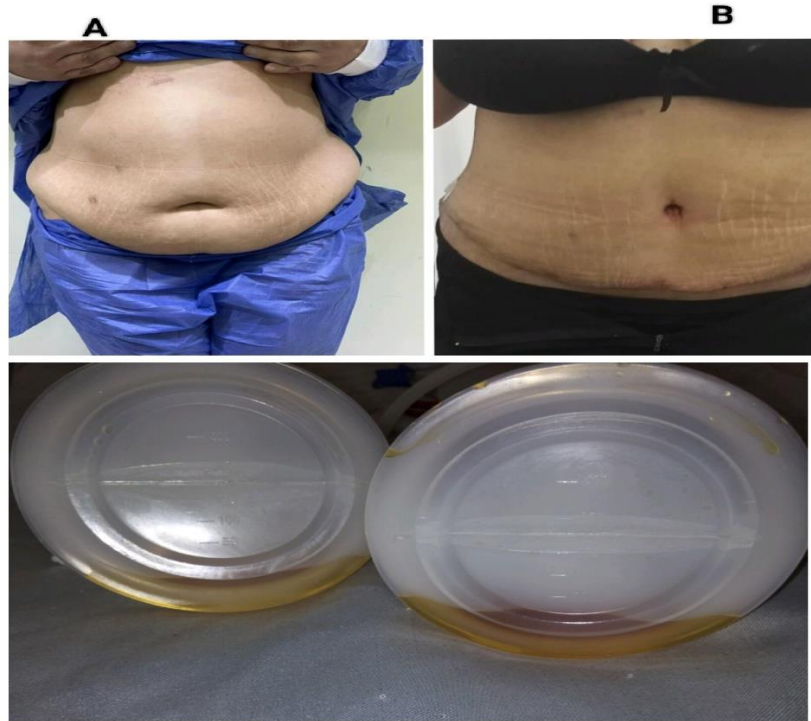


Fig. (5): Female patient 45 y old presented by pendulous abdomen following multiple pregnancy
Note: (A) preoperative photo, figure (B) 5 days post abdominoplasty with quilting sutures.

DISCUSSION

Patients having cosmetic and post-bariatric surgery have lately started to become increasingly interested in body shaping operations like **abdominoplasty**. Following abdominal surgery, the area may experience seroma formation, wound dehiscence, hypertrophic scarring, **infection**, **residual** deformity, and large umbilical scars. Numerous research **was** conducted to reduce dead space, which included Suprascarp's preservation and quilting sutures, in order to reduce seroma development following an **abdominoplasty**. Some writers have suggested that maintaining the fascia of the scarp or reducing dead space after an abdominoplasty may have a role in reducing the risk of **complications**. **This** study's objective was to compare the benefits of conserving the scarpa's fascia versus quilting sutures in reducing postoperative problems following abdominoplasty.

This is a randomized prospective study that included 30 females with pendulous abdomen. **Our patients** were randomized into two groups. Group A: (15 patients) underwent abdominoplasty with **Suprascarp's fascia preservation**. **Group B:** (15 patients) underwent abdominoplasty with quilting sutures.

Age-related differences between the two groups in our study were not statistically significant, with group A's mean age (37 ± 2) and group B's mean age (38 ± 2) ($P = 0.612$).

Also Regarding BMI, prior abdominal surgeries, or concomitant medical disorders, there was no statistically significant difference between the groups

El wakeel et al. [6], research carried out a comparable study between **(group A)** with traditional rectus sheath dissection plane with **(group B)** with supra Scarpa's dissection plane. Both groups had the same age, BMI, and liposuction volume.

Costa-Ferreira et al. [7] treated patients who underwent abdominal surgery while preserving Scarpa's fascia in the **infraumbilical** region. There was no statistically significant difference between the groups for BMI, previous abdominal operations, or concurrent medical conditions.

In our study, there were **no significant** differences in the post-operative **complications** between groups A and B with reference to seroma in 3 patients were recorded in group A and 5 patients were recorded in group B, with a *P* value of 0.409.

Similar research by **Repo et al.** [8], shown that preserving the **Scarpa's** fascia in patients who have had significant weight loss may shorten hospital stays and reduce the need for suction drains as well as the amount of seroma that arise and the overall amount of drain **output**.

Abdominoplasty with preservation of the **suprascarpa** reduced seroma production and drain duration, according to **El wakeel et al.** [6]. This is justified by the maintenance of lymphatics and subscapular fat.

Scarpa's fascia preservation during abdominoplasty has been demonstrated by **Novais et al.** [9], To decrease issues with the standard technique, the researcher used a randomized controlled trial. In this study, it will be determined whether or not keeping Scarpa's fascia after abdominoplasty impacts the quality or sensitivity of the healing scar.

Rahal et al. [10], reported that patients underwent abdominoplasty with **suprascarp's fascia preservation** decrease risk of hematoma, seroma and wound infection by preservation physiological structures (**lymphatics and blood vessels**) that allow better adhesions between abdominal flap and scarp's fascia.

Iannelli et al. [11], reported that Infra-umbilical deep adipose tissue preservation would provide preservation of vascular and lymphatic systems with a decrease in seroma development, a decrease in duration and amount of drainage, and a decrease in length **of the hospital stay, while Yasser Helmly et al.** [12], who reported **that abdominoplasty** procedure with Particular points quilting sutures (abdominopexy) are used to attach the superficial facial system to the muscles of the abdominal wall and to close the borders of tension-free wounds. decrease seroma formation post abdominoplasty.

Rodrigo Rosique, et al. [13], **reported** that the application of quilting sutures is a successful method for preventing seroma, necessitating no extra surgical **procedures**.

In our study, there were no discernible changes in post-operative blood transfusion, drain length, liposuction, or operating time. But **there's significant** difference between **suprascarp's fascia** preservation and quilting suture groups regarding drain output.

Reduced drain removal times may also result in a decreased risk of surgical complications including local infections and thromboembolic events.

Epstein et al. [14], reported that lipoabdominoplasty coupled with progressive tension sutures minimize drain length and post-operative problems, and the results support their findings in terms of drain **duration**. That since there is less dead space and there are fewer shearing pressures between the skin and the flap.

Sforza et al. [15], stated that the use of quilting sutures in abdominoplasty surgery for lowering the clinical presentation of seroma, drain output, and drain length has drastically changed the viewpoint and way of practice.

Regarding to waist definition and abdominal contour, **there was** significant difference in our study between both groups. Compared to group B with quilting sutures, group A with **suprascarp's fascia preservation** has a lower post-operative waist circumference.

our results were in agreement with **El-Shaer et al.** [16], which were rated on a scale of good, fair, or awful by the patients and who all indicated satisfaction with the outcomes.

CONCLUSIONS

This study is comparison between quilting sutures and supra scarp's dissection in reduction of seroma formation following abdominoplasty.

Scarpa's fascia preservation (SFP) modifications to abdominoplasty were linked to restricted dissection, midline musculoaponeurotic plication, and superfluous skin excision. A useful **procedure is** Scarpa's fascia inferomedial advancement flap.

This method resulted in shorter hospital stays, lower seroma development, total drain output, and time needed for suction drains.

Additionally, it can **improve surgical** outcomes while keeping the advantages of maintaining abdominal wall lymphatics, such as lowering seroma rates and shortening drain times.

Although an abdominoplasty with quilting sutures appears to be an excellent complement to body contouring since it removes the need to compromise aesthetics by limiting the amount of dissection or by skipping concomitant liposuction, it has a higher seroma rate. The complications hemostasis, necrosis, and venous thromboembolic events were also rare.

Our research has led us to the conclusion that preserving **suprascarp's fascia** is better than **quilting sutures** in decrease seroma's clinical presentation. Finally, we think that the use of drains in abdominoplasty will **eventually be limited**. It has been demonstrated to be safe, with just a few mild and no significant issues.

REFERENCES

1. **Taman N., Buchman A, and Muehlberger T.** Fibrin glue and seroma formation following abdominoplasty. *Chirurg.* 78:531–535, 2007.
2. **Neaman K. C., Armstrong S. D., Baca M. E., Albert M., Woude D. L. V. and Renucci J. D.** Outcomes of traditional cosmetic abdominoplasty in a community setting: a retrospective analysis of 1008 patients. *Plast. Reconstr. Surg.* 131(3):403-410, 2013.
3. **Costa-Ferreira A. and Rebelo M.** Scarpa fascia preservation during abdominoplasty: randomized clinical study of efficacy and safety. *Plast Reconstr Surg.* 131(3):644- 654, 2013.
4. **Wijaya W. A., Liu Y., He Y., Qing Y., Li Z.** Abdominoplasty with Scarpa Fascia Preservation: A Systematic Review and Meta-analysis. *Aesthetic Plast. Surg.* 46(6):2841-2852, 2022.
5. **Saldanha O.R., De Souza Pinto E.B., Mottos WN Jr, Pazetti C.E., Lopes Bello E.M., Rojas Y., dos Santos M.R., de Carvalho A.C. and Filho O.R.** Lipoabdominoplasty with selective and safe undermining. *Aesthetic Plast. Surg.* 200327(4):322-7, 2003.
6. **Elwakeel H., Abouarab M. H. and Kholosy H. M.** Scarpa fascia versus rectus sheath plane in lipoabdominoplasty flap dissection: comparative study. *Egypt. J. Plast. Reconstr. Surg.* 45(3), 113-119, 2021.
7. **Costa-Ferreira A., Rebelo M., Vázquez L. and Amarante J.** Scarpa fascia preservation during abdominoplasty. In: Di Giuseppe A., Shiffman M.A., eds. *Aesthetic Plast. Surg. Abdomen.* Cham, Switzerland: Springer; pp. 59-73, 2015.
8. **Repo O., Oranges C.M., di Summa P.G., Uusalo P., Anttinen M. and Giordano, S.** Scarpa fascia preservation to reduce seroma rate on massive weight loss patients undergoing abdominoplasty: a comparative study. *J. Clin. Med.* 12, 636, 2023.
9. **Novais C.S., Carvalho J., Valença-Filipe R., Rebelo M., Peres H. and Costa-Ferreira A.** Abdominoplasty with scarpa fascia preservation: randomized controlled trial with assessment of scar quality and cutaneous sensibility. *Plast. Reconstr. Surg.* 146(2):156-164, 2020.
10. **Rahal A. A., Alboudi S., Alhilbawi M. H. and Alhassanieh A.** A comparison between supra Scarpa's fascia abdominoplasty and traditional abdominoplasty: effect of caesarean section. *Modern plast. Surg.* 11(2): 37-48, 2021.
11. **Iannelli A., Ciancio F., Annoscia P., Vestita M., Perrotta R. E., Giudice G. and De Robertis M.** Abdominoplasty with "scarpa fascia" preservation: case report. *Int. J. Surg. Case. Rep.* 47:100-103. 2018.
12. **Helmy Y., Wael Ayad W., Al-Refai A. and Taha A.** Minimized dead space (Abdominopexy) plus tension free wound edges abdominoplasty. *Al-Azhar Assiut Med. J.* 18 (3):268-282, 2010.

13. **Rodrigo Gouvea, Henrique lopes, etal.** The use of quilting sutures in abdominoplasty doesn't require aspiratory drainage for prevention of seroma. *Aesth plast surg* (2010) 34:102-104.
14. **Epstein S., Epstein M.A. and Gutowski K.A.** Lipoabdominoplasty without drains or progressive tension sutures: an analysis of 100 consecutive patients. *Aesthet. Surg. J.* 35(4):434-40, 2015.
15. **Sforza M., Husein R., Andjelkov K., Rozental-Fernandes P. C., Zaccheddu R. and Jovanovic M.** Use of quilting sutures during abdominoplasty to prevent seroma formation: are they really effective? *Aesthet. Surg. J.* 35(5):574-80, 2015.
16. **El-Shaer W. M., El-Noamani S. and Hosni H.** Bilateral Scarpa's Fascia Advancement *J. Plast. Reconstr. Surg.*, Vol. 35, No. 1. 2011; 133-140. Cited from Santos E. and Muraira J.: The Waist and Abdominoplasty. *Aesth. Plast. Surg.* 22: 225-227, 1998.